

# Idiopathic Scoliosis

## Condition

A 14 old girl with a history of idiopathic scoliosis. The patient's family was most concerned with the hump the young girl had formed which had proved to be psychologically disable

## Medical Assessment

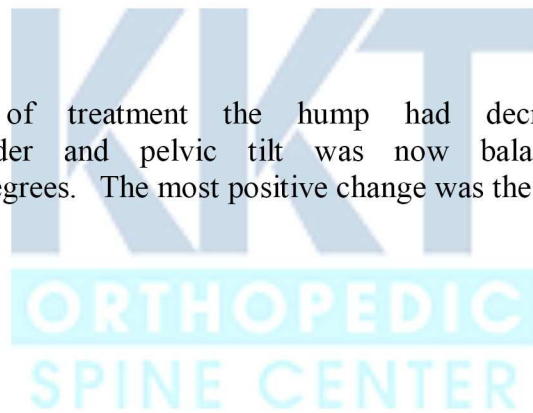
Upon examination it was determined that the patient had a right thoracic curve cobbs angle of 35 degrees and had a pelvic tilt of 2 degrees with shoulder tilt with 3 degrees.

## Treatment Suggestion

Our suggested clinical plan is to address the malalignment of the patients' spine through gently applying the KKT treatment device.

## Results of Treatment

After the six weeks of treatment the hump had decreased approximately 70 percent and her shoulder and pelvic tilt was now balanced both a zero. The cobbs angle was now 29 degrees. The most positive change was the happiness of both her and her family.



**KKT<sup>®</sup> Tomorrow's healthcare, Today!**

So come in today for a consultation and take the first step to feeling great again. Because life won't wait and neither should you!

**Get back to health and get back to being you again.**

To learn more about KKT<sup>®</sup> or to make an appointment with one of our orthopedic specialists  
Please call: +974 4434 9888, 4434 9800, 33133385